

IV. 10. A case of Autoimmune-related Pancreatitis- Usefulness of Fluorodeoxyglucose Positron Emission Tomography for the Evaluation of the Effect of Steroid Therapy -

*Takasu A., Satoh K., Satoh A., Asakura T., Nagasaki Y., Shimosegawa T., and Itoh M.**

*Department of Gastroenterology, Tohoku University School of Medicine
Cyclotron Radioisotope Center, Tohoku University**

A 73-year-old male patient was hospitalized because of repeating abdominal pain. Imaging studies showed diffusely enlarged pancreas, stricture at the distal portion of the common bile duct and diffuse narrowing of the main pancreatic duct. Laboratory data showed an increase in serum pancreatic enzymes, gammaglobuline, and some positive autoantibodies. Autoimmune pancreatitis was highly suspected. Before steroid therapy, ¹⁸F-fluorodeoxyglucose positron emission tomography (FDG PET) showed a diffuse and intense accumulation of the radioactivity in the pancreas. After starting steroid therapy, an enlargement of the pancreas was improved remarkably on CT, accompanied by an improvement of laboratory data and no accumulation of FDG was recognized on PET. It was considered that FDG PET showed an enhanced glucose metabolism in the inflammatory cells infiltrating to the pancreas before therapy and its improvement after steroid therapy. We concluded that FDG PET may be useful for evaluating the effect of steroid therapy in this disease.

Introduction

Autoimmune pancreatitis is a relatively new entity and is characterized for its remarkable improvement by steroid therapy. We report a patient with this disease in whom the effect of steroid therapy was evaluated by FDG PET.

Case report

A 73-year-old male patient developed repeating abdominal pain in early January 1999, and was admitted to another hospital. Pancreatic cancer was suspected on the basis of the radiographic findings, that is diffusely swelling of the pancreas and stricture of common bile duct. He was admitted to our hospital for further examinations on April 1st. The patient had a history of diabetes since he was 66 years old and he has been left without treatment for more than two years because control was good. He had no history of alcohol

consumption and no family history of pancreatic diseases.

On physical examination, no tumor was palpable in the abdomen, and no superficial lymphonodes were palpable.

The laboratory data on the admission showed evidence of cholestatic liver dysfunction, and elevation of pancreatic enzyme, fasting blood sugar and CA19-9. Furthermore, gammaglobuline was remarkably increased (2.65 g/dl) and immunoglobulin G was also elevated (2936 mg/dl). Antinuclear antibody (ANA) was positive and the pattern was diffuse. Anti carbonic anhydrase-II(CA-II) antibody was also positive. Antimitochondrial antibody (AMA) was negative. Pancreatic exocrine function test such as PFD test and fecal chymotrypsin test was shown to be almost normal. (Table).

Ultrasonography showed diffuse enlargement of the pancreas with a slight hypoechoic pattern. Particularly, the head of the pancreas seemed like a mass (Fig. 1 a,b). CT scans revealed diffuse enlargement of the pancreas without cyst or calcification (Fig.2 a,b). Endoscopic retrograde cholangiography (ERC) showed stricture of the distal common bile duct (Fig. 3a) and MR cholangiopancreatography (MRCP) showed irregularly narrowing of the main pancreatic duct (Fig. 3b). Autoimmune pancreatitis was highly suspected from these findings. FDG PET demonstrated a remarkably high and diffuse accumulation in the pancreas which could not deny pancreatic cancer (Fig. 4 a,b). Although operation was recommended, the patient and his family were unwilling and against it. Furthermore, he showed no symptoms after admission and laboratory data including the enzymes of the pancreas and the bile duct system and CA19-9 returned to normal during the course, and diabetes control was improved by diet therapy, so we decided to get him discharged. While being followed as an outpatient, the pancreas remained diffusely enlarged on ultrasonography and pancreatic enzymes such as serum amylase and lipase repeated elevation while he had no symptoms. On the other hand, diabetes control got worse gradually. Thus the patient was admitted to our hospital again on October 8th in 1999 for the control of diabetes and for receiving diagnostic therapy of autoimmune pancreatitis by corticosteroid. Predonisolone at an initial dose of 30 mg/day was administered orally for one week, and the dose was gradually reduced. The pancreas swelling resolved by 6 weeks after starting steroid therapy on ultrasonography (Fig. 1c) and on CT (Fig. 2 c,d), and the stricture of the common bile duct was also improved on ERCP (Fig. 3c). Along with it, the laboratory data such as elevated gammaglobuline and immunoglobuline G returned to normal and the elevation of pancreatic enzymes and cholestatic liver dysfunction was also improved. Antinuclear antibody showed negative (Table). FDG accumulation was not recognized on PET performed 8 weeks after starting steroid therapy (Fig. 4c). However, ERCP showed that the main pancreatic duct remained diffusely narrowed (Fig. 3d).

Discussion

Since Yoshida et al¹⁾ proposed the concept of autoimmune pancreatitis, numbers of authors have reported about this disease so the concept has been increasingly permeating recently. It is characterized by no symptoms or mild symptoms, diffuse swelling of the pancreas, diffuse and irregular narrowing of the pancreatic duct, cholestatic liver dysfunction caused by constriction of the common bile duct in the pancreas, hyperimmunoglobulinemia, eosinophilia, positive anti-nuclear antibody (ANA) and CA-II antibody, histologically fibrotic change with lymphocyte infiltration in the pancreas, and effective steroid therapy^{1,2)}. In our case, though histological diagnosis had not been made, it fulfilled all the other criteria of this disease. So we postulate an autoimmune mechanism as the etiology of this patient's pancreatitis.

Some experiments have suggested that this pancreatitis is mediated by a cellular autoimmune mechanism^{3,4)}. It has been reported that HLA-DR antigens were expressed on the epithelial cells of the pancreatic duct, and the pancreas was infiltrated by activated CD-4 or CD-8 positive T lymphocytes, which caused the segmental narrowing of the pancreatic duct³⁾. Carbonic anhydrase-II (CA-II) and lactoferrin existing on the exocrine cells have been considered to be possible target antigens⁵⁾.

FDG PET has been thought as useful modality for distinguishing malignant tumors from benign disease^{6,7)}. However FDG sometimes accumulates in inflammatory sites which causes false positive^{8,9)}. Recently, Nakamoto et al. has reported that FDG uptake in the pancreas with this disease was as high as pancreatic cancer lesion, therefore the differentiation from cancer is difficult and care must be paid¹⁰⁾. It may be the results of enhanced glucose metabolism in massive lymphocytes or fibroblast infiltrating to the pancreas. FDG PET performed after starting steroid therapy revealed no accumulation. It may be because the lymphocyte infiltration was improved or activation of these inflammatory cells was released by steroid therapy.

In our case, the main pancreatic duct remained diffusely narrowed on ERP, even after the swelling of the pancreas improved on CT and hypergammaglobulinemia improved by steroid therapy. Moreover, diabetes was worsened even after steroid therapy, although many authors have reported that diabetes in this disease improved by steroid therapy^{2,3)}. Recently, Tanaka et al. investigated the mechanism of developing diabetes in autoimmune pancreatitis. They have found that the number of the islet is decreased by replacement with massive fibrotic tissue and lymphocyte infiltration in the pancreas in diabetes associated with this disease, and some mechanisms of islet regeneration by steroid therapy may participate in the improvement of diabetes¹¹⁾. But details are still unknown. Concerning our case, the reason why diabetes has not been improved by steroid may be because more than five years have passed since he developed diabetes, so the fibrotic change in the pancreas involving islets may have been advanced and irreversible. Or, diabetes in this case may not have been associated with autoimmune pancreatitis.

In conclusion, although FDG PET may reveal high accumulation in the entire pancreas or focal intense uptake in patients with autoimmune pancreatitis which makes it difficult to differentiate from cancer, it may be useful for evaluating the effect of steroid therapy.

References

- 1) Yoshida K., Toki F., Takeuchi T., et al., *Dig. Dis. Sci.* **40** (1995) 1561-1568.
- 2) Ito T., Nakano I., Koyanagi S., et al., *Dig. Dis. Sci.* **42** (1997) 1458-1468.
- 3) Ohana M., Okazaki K., et al., *Am. J. Gastroenterol* **93** (1998) 99-102.
- 4) Kanno H., Nose M., Itoh J., et al., *Clin. Exp. Immunol.* **89** (1992) 68-73.
- 5) Kino-Osaki J., Nishimori I., Okazaki K, et al., *Gastroenterology* **110** (1996) 1579-1586.
- 6) Jimmy M., Bares R., Jurgen Fa β . et al., *Eur. J. Nucl. Med.* **24** (1997) 678-682.
- 7) Keogan M.T., Tyler D., Clark L., et al., *Am J. Roentgenol.* **171** (6)(1998) 1565-70.
- 8) Paul D., *Eur. J. Nucl. Med.* **25** (1998) 259-264.
- 9) Strauss L.G., *Eur. J. Nucl. Med.* **23** (1996) 1409-1415.
- 10) Nakamoto Y., Sakahara H., Higashi T. et al., *J. Clin Nucl Med* **24** (1999) 778-80, 1999.
- 11) Tanaka S., Kobayashi T., Nakanishi K., et al., *Lancet* (in press).

Table 1. Laboratory data before and after steroid therapy.

	before	after	
WBC	7700	8100	$\times 10^3$ /ml
eosinophil	693	81	$\times 10^3$ /ml
T-bil	0.8	0.8	mg/dl
ALP	515	146	IU/l
γ -GTP	285	51	IU/l
GOT	35	21	IU/l
GPT	64	32	IU/l
serum-amylase	249	112	IU/l
serum-lipase	51	3	IU/l
T.P	8.7	5.9	g/dl
γ -globuline	2.65	1.08	g/dl
Ig G	2936	1197	mg/dl
AMA	(-)	-	
ANA	(+)	(-)	
	speckled		
	homogeneous		
CA- II antibody	(+)	(+)	
CA 19-9	62.8	27.1	U/ml
Dupan 2	140	-	U/ml
FBS	366	146	mg/dl
PFD-test	69.3	67.1	%
fecal chymotrypsin test	normal	normal	

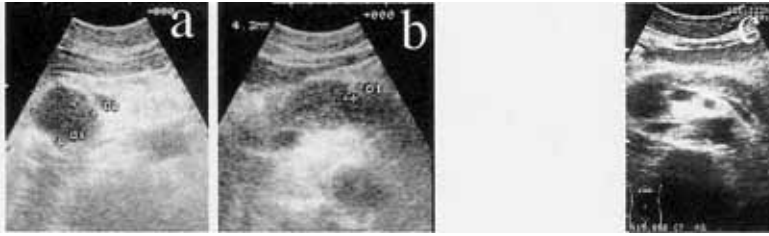


Fig. 1. a,b: Ultrasonography images on the first admission, showing sausage-like enlargement of the pancreas. Particularly, the head of the pancreas seemed like a mass. c: Ultrasonography image after starting steroid therapy revealing improvement of enlargement of the pancreas.

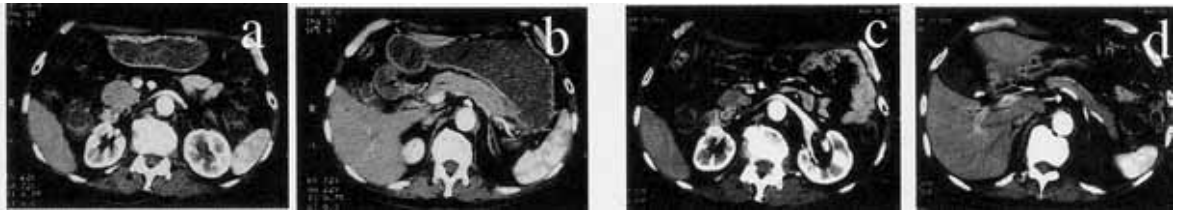


Fig. 2. a,b: Pretreatment CT scans, showing diffuse enlargement of the pancreas. c,d: CT scans after starting steroid therapy, demonstrating remarkable improvement of enlargement of the pancreas.

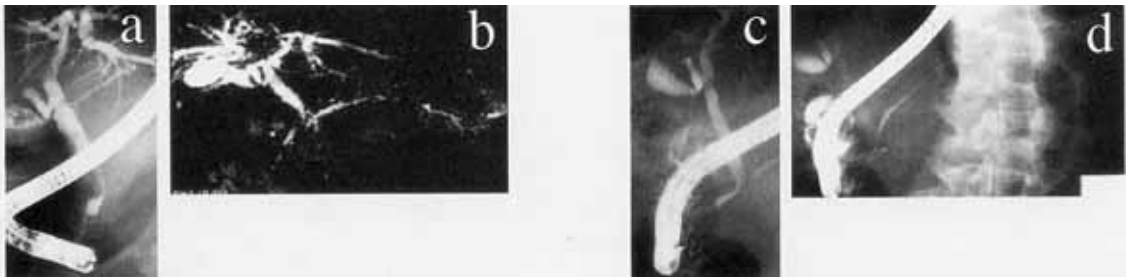


Fig. 3. a,b: Pretreatment ERC and MRCP images, showing stricture of the of the common bile duct in the pancreas and diffuse irregular narrowing of the main pancreatic duct. c,d: ERCP images obtained after starting steroid therapy, demonstrating improvement of the common bile duct stricture and remains of narrowing of the main pancreatic duct.

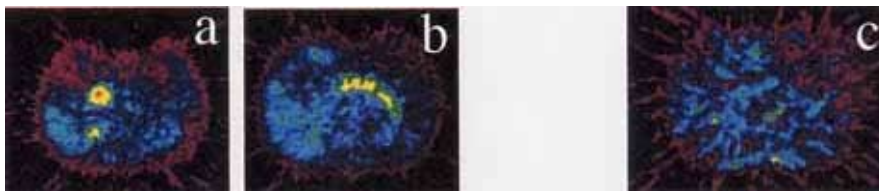


Fig. 4. a,b: Pretreatment FDG PET images, demonstrating diffuse and high accumulation in the pancreas, which could not deny malignancy. c: FDG PET image after starting steroid therapy, showing no FDG accumulation in the pancreas.