

# PRESENCE OF $17\beta$ -HYDROXYSTEROID DEHYDROGENASE ACTIVITY IN THE TISSUES OF MATURING OYSTERS

By

Katsuyoshi MORI\*, Hideo TAMATE\*\* and Takeo IMAI\*

*Departments of Fisheries\* and Animal Husbandry\*\*,  
Faculty of Agriculture, Tohoku University,  
Sendai, Japan*

*(Received July 26, 1965)*

## Introduction

No evidences had been known concerning the presence of sex control mechanisms by the steroid hormones in invertebrates (1, 2) until Botticelli et al. (3, 4) and Lisk (5) found that the steroid hormones exist in diverse groups of marine invertebrates, i.e., in starfish, sea urchin, pecten and American lobster. In the oyster tissues, we have recently demonstrated histochemically the presence of  $\Delta^5$ - $3\beta$ -hydroxysteroid dehydrogenase ( $\Delta^5$ - $3\beta$ -enzyme) activity (6). The reaction was strongly positive in the elongated epitheloid tissues adjacent to the visceral ganglion and adductor muscle, and in the interstitial cells, probably a smaller type of the amoebocytes. The enzyme is considered to be responsible for the oxidation of the  $\Delta^5$ - $3\beta$ -hydroxysteroids to  $\Delta^4$ - $3$ -ketosteroids in the process of biosynthesis of steroid hormones. This led us to the conclusion that the biosynthesis of steroid hormones might be of common occurrence not only in vertebrates but also in invertebrates including marine bivalves.

This hypothesis led us to an attempt to determine histochemically the presence of  $17\beta$ -hydroxysteroid dehydrogenase ( $17\beta$ -enzyme) activity in the oyster tissues with the evaluation of the techniques employed, because the  $17\beta$ -enzyme, together with the  $\Delta^5$ - $3\beta$ -enzyme, is one of enzymes which are responsible for the biosynthesis of steroid hormones and are demonstrable both by biochemical procedures (2, 7) and by histochemical techniques (8, 9). According to Pearson and Grose (8), the positive organs of the rat for the  $17\beta$ -enzyme reaction were liver and small intestine; however, other tissues such as the adrenal, ovary and testis were negative. A similar but somewhat contradictory result was also obtained by Levy et al. (9). Pearson and Grose did not refer to the possible involvement of the  $17\beta$ -estradiol dehydrogenase which differs from the  $17\beta$ -hydroxysteroid dehydro-

genase in preferred substrate, preferred cofactor and localization in the cell (2). We will refer to the possible existence of this enzyme in the oyster.

### Materials and Methods

The Japanese oyster, *Crassostrea gigas*, cultured for two or three years in Matsushima Bay by the raft-culture method, was used as the materials. The experiment was carried out in the maturing season from April to June in 1965. The tissues containing the nephridium adjacent to the adductor muscle, and those containing the digestive diverticulum, intestine, glycogen-bearing connective tissue and gonad of 10 oysters of both sexes were studied. In a few cases, the mantle and gill tissues were also examined.

The blocks of fresh tissues were placed in a cryostat (temperature,  $-20^{\circ}\text{C}$ ) at least for two hours. They were then sectioned at  $12\mu$ . Before incubation, the sections mounted on cover glasses were rinsed in a cold ( $4^{\circ}\text{C}$ ) acetone for 10 minutes to remove lipids. The time for treatment with acetone was prolonged in order to assure the extraction of endogenous lipids (6). They were then immersed in 0.1M phosphate buffer (pH 7.1) at room temperature for five minutes to remove the acetone and soluble endogenous substrates. They were transferred to the incubation medium containing either estradiol- $17\beta$  or testosterone propionate (final conc., ca., 5mM) as a substrate, Nitro-Blue Tetrazolium (Nitro-BT: 0.16 mM), nicotinamide adenine dinucleotide (NAD: 0.68mM) and phosphate buffer, pH 7.1 (0.057M). The incubation time was 120 minutes at  $37^{\circ}\text{C}$ . The following control media were used; estradiol- $17\beta$  without NAD, testosterone propionate without NAD, estrone plus NAD, and NAD without any substrate. The dehydroepiandrosterone or pregnenolone plus NAD medium was also employed to demonstrate the  $4^5$ - $3\beta$ -hydroxysteroid dehydrogenase activity. After incubation, the sections were treated in the same manner as reported already (6), and finally mounted on slide glasses with Canada balsam. The control sections were treated in the same manner.

The fresh tissues of the kidney, liver, duodenum, adrenal gland and ovary of the albino rat were also studied to evaluate the above techniques used by the present authors.

In our experience, the repeated use of incubation medium for more than two times (for a total of 8-10 sections) was not permissible, because it often resulted in a false, non-specific reaction in the oyster tissues which contained a large quantity of lipids.

### Observation

The histochemical demonstration of the  $17\beta$ -hydroxysteroid dehydrogenase activities in oyster tissues is presented in Table 1 and Figs. 1-10. With estradiol- $17\beta$  as a substrate, the intense enzyme activity was observed in the epithelia of

**Table 1.** Histochemical demonstration of  $17\beta$ -hydroxysteroid dehydrogenase activity in the oyster and rat tissues.  
Incubation time: 120 minutes

Animal	Substrate and Coenzyme		Estradiol- $17\beta$		Testosterone* <sup>1</sup>		Estrone plus NAD	NAD without Substrate
			plus NAD* <sup>2</sup>	without NAD	plus NAD	without NAD		
	Organ and Tissue							
Oyster	Nephridium		‡	—	+	—	—	—
	Connective tissue around the nephridium		—	—	—	—	—	—
	Adductor muscle		—	—	—	—	—	—
	Visceral ganglion		—	—	—	—	—	—
	Digestive tract	Intestine		±~+	—	—~±	—	—
		Digestive diverticulum	Duct	±~+	—	—~±	—	—
			Tubule	‡* <sup>3</sup>	—	±~+* <sup>3</sup>	—	—
	Glycogen-bearing connective tissue		—	—	—	—	—	—
	Gill		—	—	—	—	—	—
	Mantle		—	—	—	—	—	—
	Gonad	Egg		—	—	—	—	—
		Sperm		—	—	—	—	—
Interstitial cell		—	—	—	—	—		
Rat	Kidney		—	—	—	—	—	
	Liver* <sup>4</sup>		+~‡* <sup>5</sup>	—	+~‡* <sup>5</sup>	—	—	
	Duodenum	Villous epithelium		+~‡* <sup>6</sup>	—	‡* <sup>6</sup>	—	—
		Gland of Lieberkühn		—	—	—	—	—
		Gland of Brunner		—	—	—	—	—
	Adrenal gland		—	—	—	—	—	
	Ovary	Corpus luteum		—	—	—	—	—
		Follicular epithelium		—	—	—	—	—
		Theca folliculi		—	—	—	—	—
		Interstitial cell		‡	—	‡~‡	—	—

\*1 propionate

\*2 NAD=nicotinamide adenine dinucleotide

\*3 weaker or no reaction in the dark cell (or crypt cell)

\*4 incubation time: 60 minutes

\*5 reaction in the cytoplasm of liver cells

\*6 no reaction in the striated border

the nephridium (Figs. 1-5) and of the digestive diverticulum (Figs. 7-9) of seven oysters. A weak activity was also found in the epithelia of the intestine (Fig. 9). The enzyme activity was not detectable in the connective tissue surrounding the nephridium. The adductor muscle, visceral ganglion, glycogen-bearing connective tissue, gill, mantle and gonad of the oysters did not show this activity. The  $17\beta$ -enzyme reaction was also observed in the medium containing testosterone propionate as a substrate. The reaction was weaker than that with estradiol- $17\beta$ .

All experimental tissues of oysters showed no demonstrable enzyme activity after incubation in the following control media; estradiol- $17\beta$  without NAD, testosterone propionate without NAD, estrone plus NAD, and NAD without any substrate (Figs. 6, 10).

With dehydroepiandrosterone or pregnenolone as a substrate, no enzymatic activity was observed in the tissues which showed the  $17\beta$ -enzyme activity. The  $\Delta^5$ - $3\beta$ -enzyme reaction was found in the interstitial cells of the gonad and those of the glycogen-bearing connective tissue between the gonad and the digestive tracts. Most of these reactive interstitial cells were probably not the amoebocytes. A detailed report concerning these cells will be presented at another opportunity.

Occasionally, a faint reaction was observed in the epithelia of the digestive diverticulum and intestine in the control media containing NAD, when the time of treatment with acetone was only for five minutes. This result, as reported previously (6), indicated that the reaction was due to some other dehydrogenases reacting on the remaining endogenous substrates.

In the rat, as shown in the lower column of Table 1 and in Figs. 11-14, the  $17\beta$ -hydroxysteroid dehydrogenase reaction in the medium containing estradiol- $17\beta$  as a substrate was found in the cytoplasm of the liver cells (Figs. 11, 12), the villous epithelium of the duodenum (Fig. 13), and the interstitial cells of the ovary (Fig. 14). The enzyme reaction was negative in the kidney, the glands of Lieberkühn and Brunner of the duodenum, and the adrenal gland. The corpus luteum, follicular epithelium and theca folliculi of the ovary were also negative. The  $17\beta$ -enzyme reaction was also found in the medium with testosterone propionate. Contrary to the oyster tissues, there was no remarkable difference in the intensity of the enzyme reaction in the two media.

The reaction was not observed in the rat tissues after the incubation in the control media, i.e., estradiol- $17\beta$  without NAD, testosterone propionate without NAD, estrone plus NAD, and NAD without any substrate.

### Discussion

In our previous paper (6), we have demonstrated the presence of the  $\Delta^5$ - $3\beta$ -hydroxysteroid dehydrogenase activity in the tissues of maturing oysters. In the present study, the histochemical reaction of the  $17\beta$ -hydroxysteroid dehydrogenase was demonstrated in the epithelia of the nephridium and digestive tracts including

the intestine and digestive diverticulum. The enzyme reaction was not observed in other tissues; the connective tissue around the nephridium, adductor muscle, visceral ganglion, and glycogen-bearing connective tissue. The gill, mantle and gonad did not show the activity. The reaction was not detectable in all control media, and therefore the techniques in this study seemed to be reliable.

In the rat, the cytoplasm of the liver cells, villous epithelium of the duodenum, and interstitial cells of the ovary showed  $17\beta$ -enzyme activity after the incubation in the medium containing estradiol- $17\beta$  or testosterone propionate as a substrate. The enzyme activity was not found in other tissues; kidney, glands of Lieberkühn and Brunner of the duodenum, and adrenal gland. The corpus luteum, follicular epithelium and theca folliculi of the ovary were also negative. It is interesting that  $17\beta$ -enzyme activity was found in the digestive organs in both animals, namely, in the digestive diverticulum and intestine of the oyster, and in the liver and duodenum of the rat. The enzyme reaction in the rat tissues was in agreement with that of Pearson and Grose (8) on the same organs. The only difference was that they did not find the activity in the interstitial cells of the ovary. However, Levy et al. (9) observed the activity in the same cells. The validity of the techniques in this study, therefore, was confirmed by the experiment carried out on the rat, as well as by the control one on the oyster.

According to the report of Levy et al. (9), the enzyme activity on the  $17\beta$ -hydroxysteroids was also detectable in the steroid-producing cells such as the adrenal and the corpus luteum of ovary, as well as in the liver, kidney and oviduct epithelium. They reported that the repeated use of incubation medium for about five times (for a total of 20-25 sections) was permissible in their study. So far as we experienced, repeated use for more than two times (for a total of 8-10 sections) was not permissible, because it often resulted in a false, non-specific reaction in the oyster tissues which contained a large quantity of lipids. Therefore, their observation might possibly be due to the over-repeated use of incubation medium.

In the oyster tissues, the  $17\beta$ -enzyme reaction was weaker with testosterone as a substrate than with estradiol- $17\beta$ . In the rat tissues, there was no remarkable difference in the intensity of the enzyme reaction with the two media. This finding in the rat tissues is in accord with that of Pearson and Grose (8). Therefore, the difference might result not from the poor solubility of testosterone, but from the substrate specificity of the enzyme in the oyster. The presence of the  $17\beta$ -estradiol dehydrogenase which is specific for  $17\beta$ -estradiol, has been reported (2). The result obtained in the oyster tissues suggests the possible existence of this enzyme in this species. A report on this matter will be given at a later opportunity.

The result obtained in the present study together with that of our previous one (6) strongly suggests the possibility that steroid hormone metabolism does exist in the oyster. This possibility has also been suggested by the report of Botticelli et

al. (4) on the presence of estrogens and progesterone in the pecten.

### Summary

The results of this study are summarized as follows:

1.  $17\beta$ -Hydroxysteroid dehydrogenase activity was demonstrated histochemically in the Japanese oyster, *Crassostrea gigas*, collected in the maturing season from April to June in 1965.

2. The enzyme activity was observed in the epithelia of the nephridium, digestive diverticulum and intestine. This activity was not detectable in the connective tissue surrounding the nephridium, or in the tissues of the adductor muscle, visceral ganglion, glycogen-bearing connective tissue, gill, mantle and gonad of any of the oysters.

3. In the rat tissues, the cytoplasm of the liver cells, the villous epithelium of the duodenum, and the interstitial cells of the ovary showed the enzyme activity. The activity was not found in the kidney, glands of Lieberkühn and Brunner of the duodenum, adrenal gland and ovarian tissues including the corpus luteum, follicular epithelium and theca folliculi. This observation was in agreement with that of Pearson and Grose (8) on the same organs except the interstitial cells of the ovary.

4. The validity of the techniques in this study was confirmed by the experiment carried out with the rat, and also by the result that no reaction was found with the control media.

5. The result obtained in the present study together with that of our previous one (6) strongly suggests the possibility that steroid hormone metabolism does exist in the oyster.

### Acknowledgement

The present authors wish to express their thanks to Prof. Osamu Itikawa for his guidance and criticism throughout this study. Thanks are also due to Mr. Sadamitsu Yoneya for his technical assistance.

### References

1. Brown, F.A., Jr. (1952). Comparative Animal Physiology (ed. by C.L. Prosser). W.B. Saunders Company, Philadelphia, U.S.A., p. 725.
2. Samuels, L.T. (1960). Metabolic Pathways (ed. by D.M. Greenberg). Academic Press, New York, U.S.A., p. 431.
3. Botticelli, C.R., F.L. Hisaw, Jr., and H.H. Wotiz (1960). Proc. Soc. Exp. Biol. and Med., **103**, 875.
4. Botticelli, C.R., F.L. Hisaw, Jr., and H.H. Wotiz (1961). *ibid.*, **106**, 887.
5. Lisk, R.D. (1961). Canad. J. Biochem. Physiol., **39**, 659.
6. Mori, K., H. Tamate and T. Imai (1964). Tohoku J. Agr. Res.,

- 15(3), 269.
7. Talalay, P. (1957). *Physiol. Rev.*, **37**, 362.
  8. Pearson, B. and F. Grose (1959). *Proc. Soc. Exp. Biol. and Med.*, **100**, 636.
  9. Levy, H., H.W. Deane and B.L. Rubin (1959). *Endocrinology*, **65**, 932.

**Plate 1**

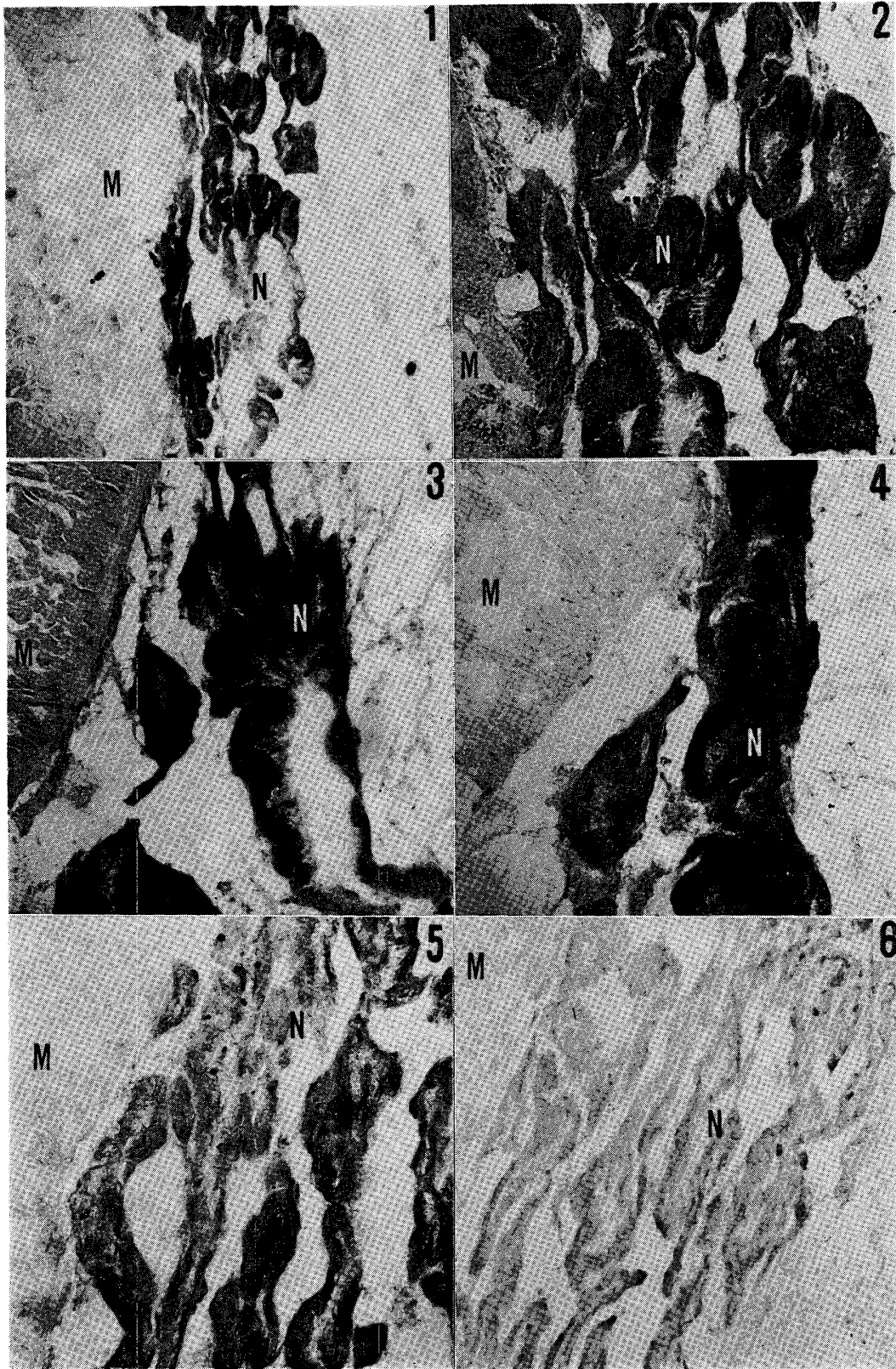
## Explanation of the Figures

All microphotographs were taken with the  $12\mu$  fresh frozen sections fixed in 10 per cent neutral formalin after incubation for 120 minutes at  $37^{\circ}\text{C}$ . The incubation medium contained estradiol- $17\beta$  (final concn., ca.  $5\text{mM}$ ), Nitro-BT ( $0.16\text{mM}$ ), NAD ( $0.68\text{mM}$ ) and phosphate buffer, pH 7.1 ( $0.057\text{M}$ ). The control medium lacked estradiol- $17\beta$ .

Figs. 1-5.  $17\beta$ -Hydroxysteroid dehydrogenase reaction in the epithelia of oyster nephridium (N) adjacent to the adductor muscle (M). Kernechtrot nuclear stain. Fig. 1,  $\times 60$ , Figs. 2-5,  $\times 150$ .

Fig. 6. Control section of the same tissue as in Fig. 5. No reaction is observed. The nuclei are stained by Kernechtrot.  $\times 150$ .





**Plate 2**

## Explanation of the Figures

Figs. 7-9.  $17\beta$ -Hydroxysteroid dehydrogenase reaction in the epithelia of duct (D) and tubule (T) of oyster digestive diverticulum. In the tubule, a considerable reaction is seen mainly in the light cells (LC) which are hardly stained by haematoxylin. A weaker or no reaction is observed in the dark cells (or crypt cells) (DC) which are stained strongly by haematoxylin. The enzyme activity is also detectable in the epithelia of intestine (I) (Fig. 9). Kernechtrot nuclear stain.  $\times 150$ .

Fig. 10. Control section of the same oyster tissue as in Fig. 8. The nuclei are stained by Kernechtrot. No deposits of formazan.  $\times 150$ .

Figs. 11 & 12.  $17\beta$ -Hydroxysteroid dehydrogenase reaction in the cytoplasm of rat liver cells. Kernechtrot nuclear stain. Fig. 11,  $\times 150$ . Fig. 12,  $\times 600$ .

Fig. 13.  $17\beta$ -Hydroxysteroid dehydrogenase reaction in the villous epithelium (V) of rat duodenum. The nuclei are stained by Kernechtrot.  $\times 150$ .

Fig. 14.  $17\beta$ -Hydroxysteroid dehydrogenase reaction in the interstitial cells (IC) of rat ovary. The nuclei are stained by Kernechtrot.  $\times 600$ .

